

Case History 1 (Wounds) “Larz”

In this picture is a 5 year old novice event horse who received an injection in the neck from the vet. Unfortunately this introduced a Clostridia infection which set up a gas gangrene which tracked down the neck and into the pectoral area at the front of the chest. The gangrene resulted in necrosis of skin and some of the muscle. These photographs were taken 12 months post infection and it is remarkable that he survived. He spent several weeks under intensive therapy at Bristol Veterinary Hospital and was not expected to survive let alone compete again.

The wound was not healing as quickly as the vet would have liked and also there was significant scar tissue which was uncomfortable for the horse. The vet also felt that it was worth seeing if the horse could cope with any sort of work. Bearing in mind that the horse has lost significant muscle mass from muscles which support the forehead such as the pectorals, and also from the brachiocephalic and sternocephalic muscles, it was felt that he would not be able to stand up to ridden work.

He was referred by the vet for me to

1. Stimulate healing over the debrided area of the wound
2. Break down some of the significant scar tissue
3. Bring him into work
4. Ascertain whether he would ever be rideable again.

This was a difficult case and the horse came to me as an “in-patient”. I used laser therapy to stimulate the epithelial cells around the edges of the skin – see picture 2. Laser therapy uses light to stimulate the skin cells in a similar way in which plants use light for photosynthesis and can deliver large amounts of energy to injured tissue in a short period of time.

Laser therapy is the generic term for all types of phototherapy. The acronym LASER stands for Light Amplification by Stimulated Emission of Radiation. In the equipment I

use for phototherapy, the application frequencies of the visible and invisible emitters act upon the surface of the skin for visible red, and just under the skin for infra-red. The photo-biological effect is to alter the cell membrane potentials causing vasodilation of blood capillaries and the increase of nutrient transfer across the cellular membranes. This stimulates epithelial (skin) cells. The increased blood flow and stimulation in these areas helps to speed up the repair of lesions and injuries.

Within a week the skin around the edges of the wound was growing rapidly. To break down the scar tissue I used therapeutic ultrasound and cross friction massage to soften and break down the bonds of the adhesions. Therapeutic ultrasound bombards the tissues with sound waves and one of the effects of this is to produce a thermal effect (a heating) of the tissues – in this particular case the scar tissue. When the tissue is warm it becomes more pliable and I can then use my fingers to stretch the scar tissue and release the adhesions. This allowed the horse more freedom of movement and stopped the scar tissue breaking down and bleeding, thus making it less uncomfortable.

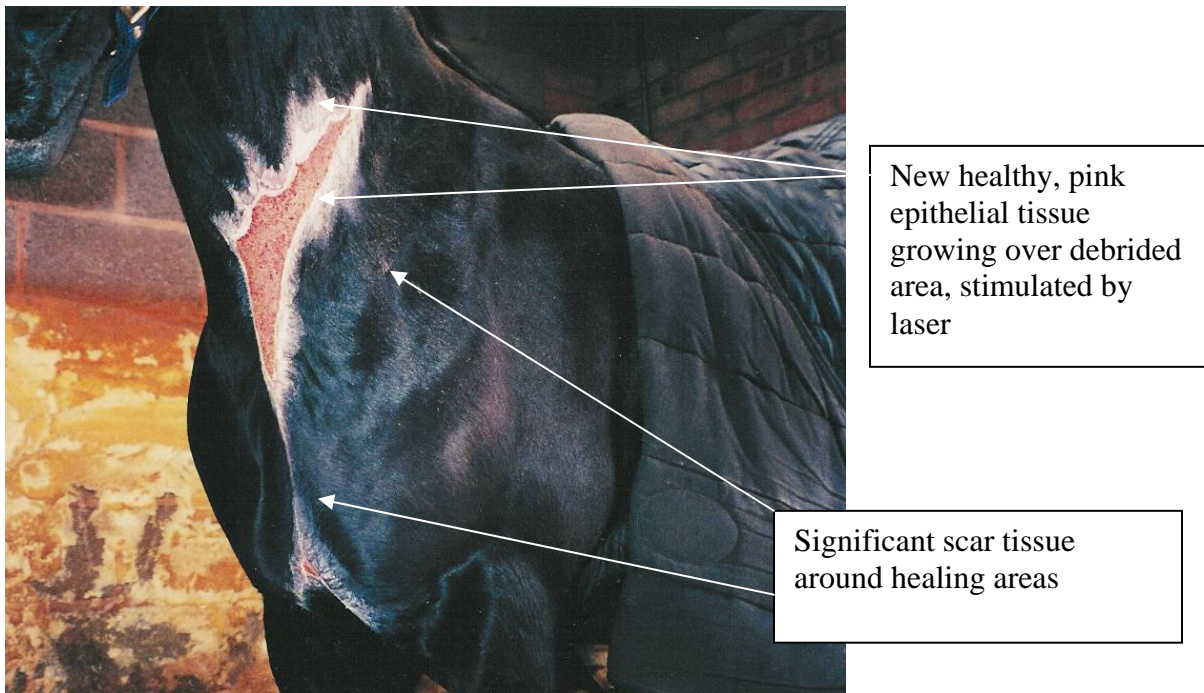


Fig 1. 12 months post infection. The new healthy pink epithelial tissue simulated by laser therapy can be seen around the edges of the wound. Also note the extensive scarring, particularly in the pectoral area which was causing the horse discomfort on movement.



Fig. 2 Using laser around the edges of the wound

I brought him back into work using a Pessoa training aid and long reins, utilising gymnastic exercises over poles. My goal was to strengthen the muscles around the shoulder to support the forehand and provide an easy foreleg action. To achieve this the horse has to be made to work through the back and up through the shoulder. By working him on the Pessoa in a long and low outline with his head lower than his withers this makes the back supple and frees the shoulder. This horse improved so much that within a month I was able to get his owner back in the saddle and the horse is now back competing again.

Case History 2 “Storm”

In this set of photographs is a wound to the side of a race horse mare who had been spooked whilst being led through a gate and had caught her side on the bolt of the gate. The wound had been stitched but the vet was concerned that the flap in the centre of the wound would not be viable for lack of circulation. Unfortunately he was correct and the skin flap failed and the mare pulled it off with her teeth one night and the whole wound became infected.

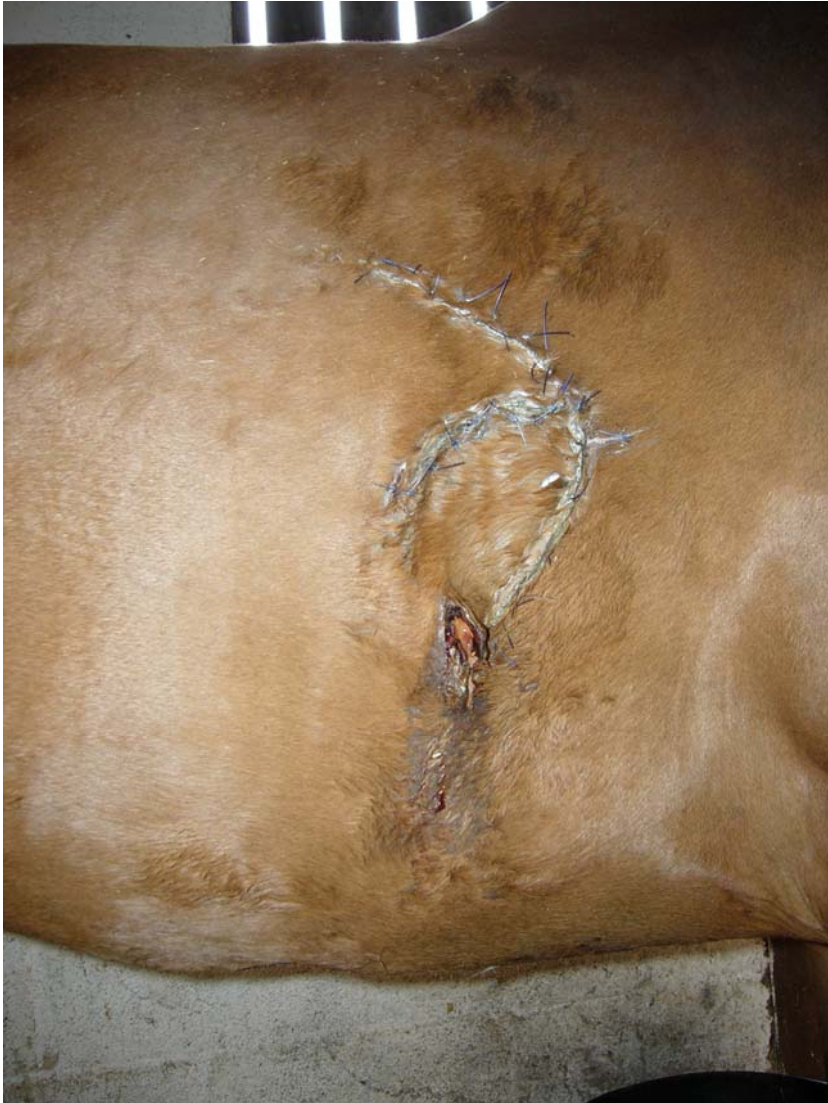

Fig.3 The wound after it had been stitched and stapled by the vet.

In cases of infected wounds the latest physiotherapy treatment is by way of “blue light therapy”. Blue light therapy is being increasingly used in the treatment of humans for such conditions as acne and there is some exciting research being carried out on the effects of blue light therapy on melanoma. The blue light spectrum used in treating infected wounds targets the bacterial cells and kills those without killing the skin cells. Once the infection has been treated normal red laser therapy can be used to stimulate the growth of skin cells.

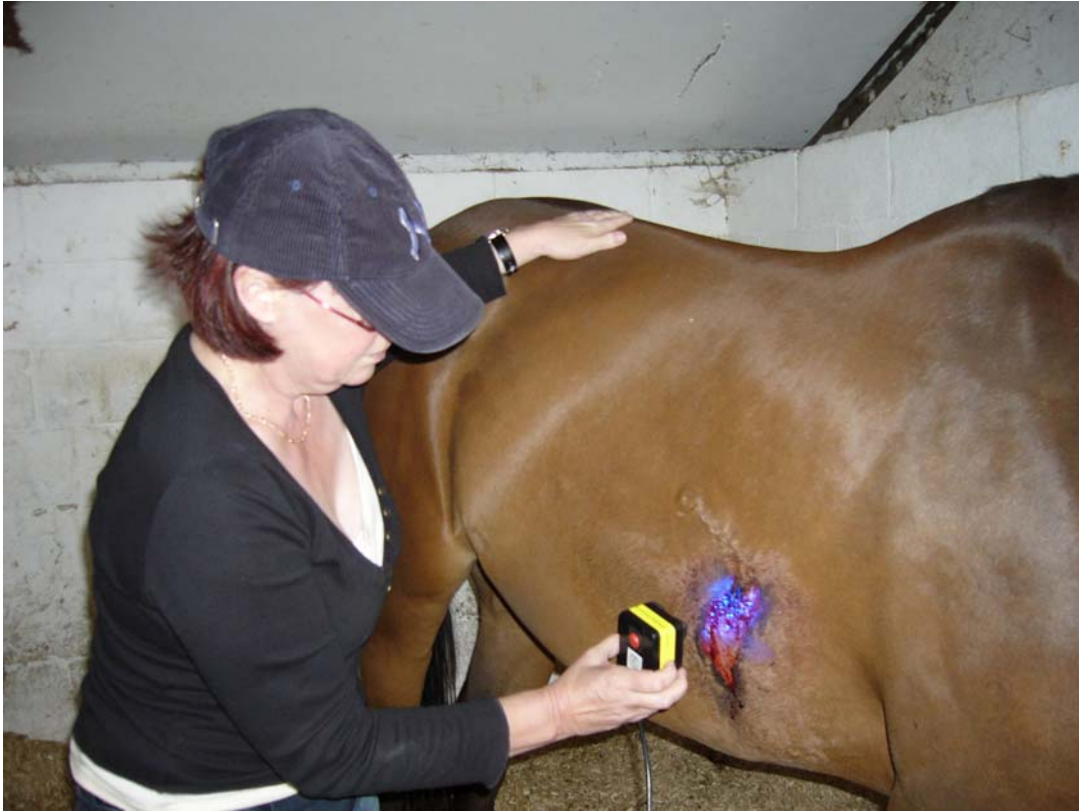

Fig. 4. Using blue light therapy on the infected wound

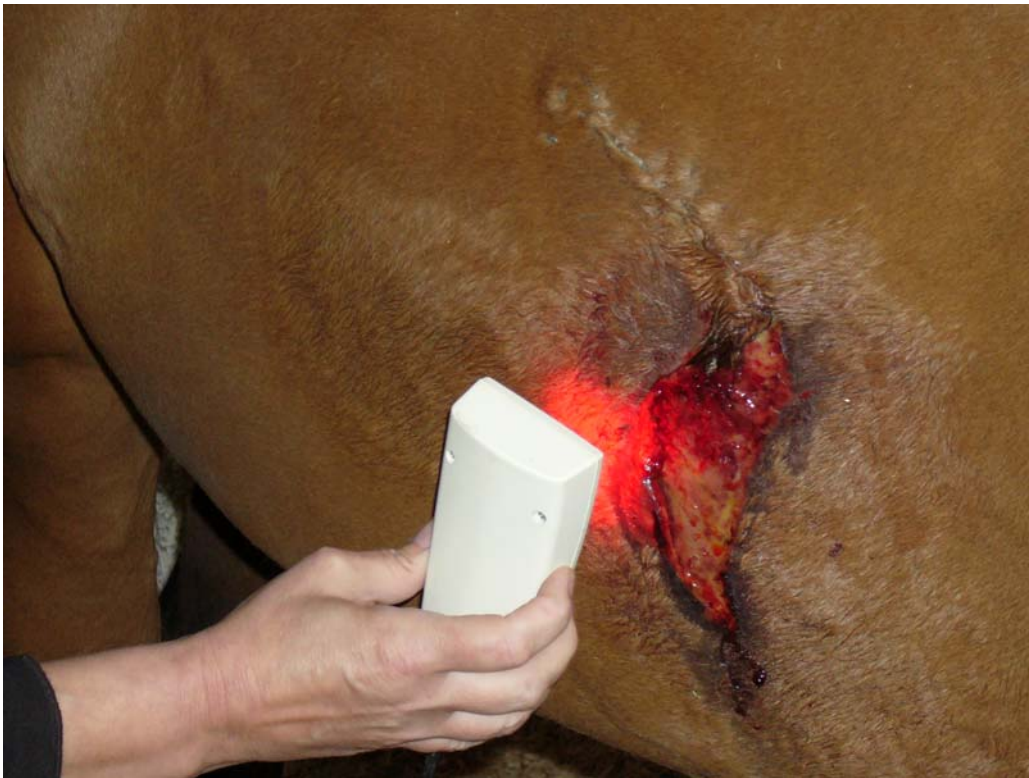

Fig. 5 Once the infection is cleared, red laser is used to stimulate skin healing.

You can see from the pictures the large debrided area where the skin flap had failed. As in the previous case history the wound has to heal by the skin growing in from the edges and the more quickly the wound heals the sooner the horse can go back into work. In the race horse there are financial pressures on the trainer to get the horse back racing as soon as possible and many race horse trainers use qualified physiotherapists to assist the healing of injuries.

In this particular case with treatments twice weekly, the horse was back in work with a healed wound in 4 weeks. As can be seen from this final photograph after she has been sponged down after working even the hair grows back and the rest of the scar will fade over the next few weeks. The best possible healing for this wound was even more important because it lies directly under the girth. In cases of incomplete healing or where fragile scar tissue is present the wound could completely break down again forcing the horse out of work .

